ISSN: 03875547
Volume 44, Issue 06, December, 2021

Six Months Clinical Outcome After Tumor Removal and Posterior Stabilization on T9-L1 in a Schwannoma Patient: A Case Report

Otman Siregar[1], Robby Oscar Sitohang[2], Pranajaya Dharma Kadar[1], Heru Rahmadhany[1], Benny[1]

Consultant of Orthopedics and Traumatology, Faculty of Medicine, University of North Sumatra/ Haji Adam Malik Hospital-Medan[1]
Consultant of Orthopedics and Traumatology, Spine Division, Faculty of Medicine, University of North Sumatra/ Haji Adam Malik Hospital-Medan[2]

Keywords:
Schwannoma, SF-36, Oswestry disability index, Modified Barthel index

ABSTRACT

Schwannoma makes up of 85% of nerve sheath tumors. It is a slow-growing benign tumor and initially causes nonspecific symptoms such as segmental pain and paresthesia. The surgical goal is to perform complete tumor removal, which had been reported to produce good clinical outcome. The aim of this case report is to show the six months clinical outcome after tumor removal and posterior stabilization of a T9-L1 in schwannoma patient based on the 36 items short form survey (SF-36), Oswestry Disability Index (ODI), and Modified Barthel Index (MBI). A 50 yead old female patient who complained of back pain and radiating leg pain during the last 6 months, weakness on the left limb, and limitations of daily activities was presented. Physical examinations, magnetic resonance imaging (MRI) evaluations, and histopathological features showed a confirmed schwannoma. Six months after tumor removal and posterior stabilization on T9-L1, the patient showed improvements on SF-36, ODI, and MBI scores. The patient's initial presentation, physical examinations, MRI and histopathology investigations, as well as pre- and post-operative score assessments results were typical of schwannoma and supported by various literature. Satisfactory clinical outcomes based on SF-36, ODI, and MBI scores were achieved after tumor removal and posterior stabilization in schwannoma patient.

1. INTRODUCTION

Schwannoma is one of the most common intradural-extramedullary (IDEM) tumor and makes up for 85% of nerve sheath tumors. The tumor commonly occurs in the thoracic region. Complete tumor removal of schwannoma had been reported to produce good clinical outcome, especially in relieving pain and recovery from neurological deficit [1]. This report describes the outcome after tumor removal and T9-L1 posterior stabilization in a schwannoma patient based on the 36 items short form survey (SF-36), Oswestry disability index (ODI), and modified Barthel index (MBI).

2. Case Report

A 50 years old female patient presented with 6 months of back pain that radiated to the leg followed by weakness on her left limb that limit her daily activities. She has no history of weight loss. From physical examination of the back, there was a tenderness with limited lumbar motion. On neurological examination: muscles tone were grade 4 in lower extremity. The sensory was in good condition and intact Anal tone. The patient presented without any pathological reflex.

The MRI showed a spinal intracanal hypointense lesion on T1W which became isohyperintense on T2W, short tau inversion recovery (STIR), lobulated, with the size of approximately 1.7 x 4.8 cm, on the level of T11-L1, well circumscribed from the adjacent T11-L1 vertebral bodies, and compressing the spinal cord. All hematologic laboratory results were normal.

Figure 1. Lesion on MRI

SF-36, ODI, and MBI questionnaires were filled out pre-operatively. SF-36 evaluation result is described in Table 1. The ODI evaluation showed the score of 84%, which meant that the patient was bed-ridden. The MBI score was 36%, that was interpreted that the patient was unlikely to go home, dependent in mobility as well as self-care.

A surgical tumor removal and posterior stabilization was selected for the patient. During operation, the lesion was found extending from T9-L1. The tumor was then removed wholly and carefully. For the posterior stabilization, L 5.5 x 45 mm pedicle screws were applied on the T8 and T9, while L 6.5 x 40 mm pedicle screws were applied on the L1 and L2. Rods were applied bilaterally and bone graft was inserted. Bio-glue was applied above the spinal cord. Lastly, a 12 G drain was applied and soft tissues and skin were closed layer by layer. There was no major significant post-surgical complication encountered.

Figure 2. Intra-operative Features; (A) Identification of tumor lesion; (B) Resected tumor; (C) Posterior stabilization

Macroscopically, the tumor was a yellowish gray 4 x 1.5 cm lesion. Microscopically, the lesion consisted of both dense/hypercellular (Antoni A) and loose/hypocellular (Antoni B) tissues. On the areas of hypercellularity, the cells were grouped together in a palisade form making a Verocay body. The cells had various forms of nuclei, from oval to spindle, with evenly spread chromatin, thin cytoplasm, and were eosinophilic. Some cells had curled nuclei. Vascular dilation and congestion were also found. It was concluded that the tumor was a schwannoma.

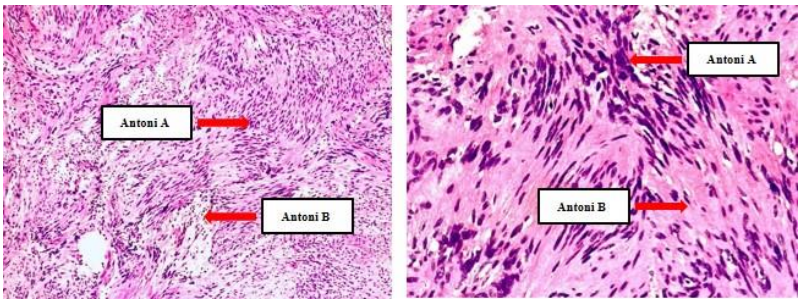

Figure 3. Histopathological Finding

Six months after surgery, the patient was evaluated for the SF-36, ODI, and MBI questionnaires. The six-month post-operative SF-36 evaluation result is described in Table 1. The ODI evaluation showed the score of 18%, which meant that the patient could cope with most living activities. The MBI score was 96%, that was interpreted that the patient was likely to community living, independent in transfers, and able to walk or use wheelchair independently.

Table 1. SF-36 score

Variables	Preoperative Score	Postoperative Score
Physical functioning	5%	60%
Role limitations due to physical health	0%	100%
Role limitations due to emotional problems	0%	100%
Energy / fatigue	30%	60%
Emotional well-being	36%	60%
Social functioning	25%	75%
Pain	22.5%	77.5%
General health	35%	60%
Health change	0%	100%

3. Discussion

The presenting symptoms depend on the tumor's location and the degree of the spinal cord or the nerve root compression. Patients usually complain about pain, motor deficits, paresthesia and numbness. Differential diagnosis based on MRI findings of schwannoma is a meningioma. On T1W images, MRI signal intensity and heterogenecity are not significantly different between meningiomas and schwannomas, while on T2W images, the signal intensity appeared significantly hyperintense and heterogeneous for schwannomas [1]. This is in accordance to the findings of this case. Histopathological findings showed Antoni A and Antoni B patterns, Verocay bodies, and various forms of nuclei including spindle. This was parallel with a literature review by Belakhoua and Rodriguez, who stated that histologically, schwannomas contain compact patterns or Antoni A, alternating with loose patterns or Antoni B. The Antoni A zones are characterized by increased cellularity and spindle nuclei. The Antoni B zones are disorganized arrangements that are hypocellular and

feature a variable macrophage infiltrate [2]. The patient in this case showed improvement based on the SF-36 evaluation. The improvements existed in all parameters. This was in accordance with a study by which evaluate the pre- and post-operative SF-36 score in schwannoma patients. The authors evaluate 1 month and 1-year post-operative score. They found improvements in all parameters, and like this case, the parameters of role limitations due to physical health and emotional problems achieved 100% [3].

The improvement based on ODI evaluation was also obtained in this case. A similar result was also showed in a study by which evaluated the pre- and post-operative ODI in thoracolumbar schwannoma patients treated with tumor removal and posterior instrumentation. The authors found the mean pre-operative ODI of 62.8±11.8 which significantly improved post-operatively into 16.9±9.5 [4].

The MBI score in this patient was improved and the patient was considered able to perform activities of daily living and self-care independently. Both the clinical outcome and quality of life in patients after schwannoma removal had been proven to be improved in several studies [5].

4. Conclusion

Schwannoma is a benign IDEM tumor that could be devastating for the patients both physically and mentally, and in this case it was proven by the evaluation of SF-36, ODI, and MBI score. Diagnosis is based on histopathological evidence. Surgical total removal is the gold standard of treatment. Satisfactory outcomes based on the three scoring systems were obtained and supported by various studies.

5. References

[1] Hohenberger C, Hinterleitner J, Schmidt NO, Doenitz C, Zeman F, Schebesch KM. Neurological outcome after resection of spinal schwannoma. Clinical Neurology and Neurosurgery. 2020 Nov 1; 198:106127.

[2] Belakhoua SM, Rodriguez FJ. Diagnostic Pathology of Tumors of Peripheral Nerve. Neurosurgery. 2021 Mar;88(3):443-56.

[3] Aman R, Nugroho Y, Nugroho A, Saekhu M, Tandian D, Ashari S, et al. Luaran Nilai Fungsional Kasus Tumor Primer Spinal Intradura Ekstramedula Pascaoperatif di RSUPN Dr. Cipto Mangunkusumo 2014-2016. eJournal Kedokteran Indonesia. 2019;7(2).

[4] Deng Q, Tian Z, Sheng W, Guo H, Dan ME. Surgical methods and efficacies for cervicothoracolumbar spinal schwannoma. Experimental and therapeutic medicine. 2015 Dec 1;10(6):2023-8.

[5] Setiawan E, Alhuraiby SS. Functional outcome in intradural extramedullary tumor patients: Case series. Annals of Medicine and Surgery. 2020 Jun 1; 54:71-3.