ISSN: 03875547
Volume 44, Issue 05, October, 2021

Intraperitoneal rupture of liver hydatid cyst: A Case Report of post-bariatric surgery and Narrative Review

Selmy Awad[1*], Fahad H Qahtani[2], Faisal S Alsulaimani[2], Mohamed M Shaat[2], Mazin A Ali[2], Ahmad H Khalid[2], QASEM M ALHARTHI[2], Musab A. ALThomali[2], Shabab S Althobaiti[2], Nadiah G.AlAmri[2], Abdullah M Alturkistani[2], Abdullah A Alshamrani[2], Amal A Ali[2], Ahmed H Alsufyani[2], Fahad M AlSofyani[2], ABDULLAH A ALGHURAYBI[2], Sondos A Alqahtani[2], Amer M Alnefaie[2], Shuruq A Alharthi[2], Abdulrahman A. Almalki[2], Abdulrahman S Alghamdi[2]

Faculty of medicine, Mansoura University, EGYPT[1]
King Faisal Medical Complex, Taif, KSA[2]

Corresponding author: 1*

Keywords:
perforation, Hydatid, post-bariatric, laparoscopy, Intraperitoneal.

ABSTRACT

Generally, hydatid cysts present asymptomatically, and a radiographical examination for another reason leads to the cysts being discovered by accident. The symptoms of some patients may depend on the location, size, and relationship between the cyst and the adjacent structures. There is a high risk of perforation of the cysts into adjacent structures, such as a biliary tree, major vessels, hollow viscera, and the peritoneum. The aim of this report is to provide an overview of a case with an unusual hepatic hydatid cyst rupture (post- bariatric) accompanied by an in-depth review of the literature. Our hospital was approached by a female patient of 46 years with a history of abdominal pain, diarrhea, and hypotension. The hepatic cyst had spontaneous rupture. IgG results of enzyme-linked immunosorbent assays were negative. Two days before laparoscopic surgery, the patient was given urgent resuscitation and treated with albendazole. Following the surgery, no recurrence was seen (22 months postoperatively). Hydatid cysts can develop an extremely rare and life-threatening complication, intraperitoneal perforation, after a significant weight loss. After judicious medical treatment for allergic reactions, it is essential to treat the patients with appropriate emergent surgical management (including laparoscopy) as quickly as possible.

1. INTRODUCTION

The hydatic disease is a zoonotic disease which is common in pastoral communities, and it is caused by a member of parasites of the Taenidae family called echinococcus [1- 3]. The disease is commonly associated with the liver (50%-77%), the lungs (15%-47%), the spleen (0.5%-8%), and the kidneys (2%-4%), but hydatid diseases may affect almost any organ [1- 6]. The final intermediate host in Echinococcosis' biological life cycle will be a human ingesting dog and sheep eggs [1], [4]. Most Hydatid cyst patients remain asymptomatic for years and are usually diagnosed incidentally by radiological examinations for

other reasons as the cyst grows at a rate of 1-50 mm/year, depending on its site [3], [7], [8]. The symptoms and signs of hydatidosis may range from nausea and vomiting to abdominal pain (mild to severe) and icterus, depending on the size, location, and/or relation to surrounding structures [1]. Complications of the cyst may include perforation (rupture), anaphylactic reaction, bacterial infection, and compression on the adjacent structures [4], [5]. Perforation of the hydatid cyst can be internally (into the hollow viscera, cysto-biliary fistula, bronchopleural fistula, broncho-biliary fistula, intrapericardial perforation, intraperitoneal perforation, intrapleural perforation) and it is rare to be externally into the skin (cysto-cutaneous fistula) [3]. An intraperitoneal perforation is a potentially life-threatening condition [33].

1.1 Review Point

The point of this deliberate review is to present a case report of an intraperitoneal perforation with unusual presentation after weight loss (post-bariatric surgery) gathered with a review article about detailed management.

2. FINDINGS AND DISCUSSION

2.1 Case Presentation

2.1.1 Main complaints

The 46-year-old lady came to the ED with abdominal pain, drowsiness, and hypotension. She denied any trauma.

2.1.2 Present history of illness

she has had the simple liver cysts approximately nine months ago and the cysts were visualized by a radiological examination (routine abd. US) during the routine preoperative investigation for laparoscopic sleeve gastrectomy. The patient was presented to ED with sudden abdominal pain, drowsiness, and hypotensive shock with no history of trauma. She was admitted at the medical ward by diagnosis of systemic hypotension for 3 days. The pain was diffuse all over the abdomen mainly epigastric and right hypochondrial areas, sudden in onset, Colicky in nature, mild to moderate in severity, progressive and aggravated by eating with no relieving factors. It was associated with anorexia and multiple episodes of vomiting. No hematemesis, melena, bleeding per rectum nor jaundice were present. Night sweating and fever were denied with unremarkable systematic review. The patient was improved and discharged on medical treatment for 3 days during when the patient condition had worsened and associated with watery diarrhea so, the patient was readmitted again under the care of gastroenterology as a case of severe gastroenteritis and subsequently shifted to ICU due to progressive profound hypotension and shock associated with desaturation where the patient was given supportive treatment with close monitoring. CT abdomen with contrast was organized and secured which showed suspected ruptured hydatid cyst with peritonitis and rapid shift to surgical care was conducted with prompt preparation for surgical intervention using laparoscopy after patient optimization. laparoscopic management was performed after 2 weeks duration from the 1st presentation. Upon physical examination, the patient looked ill and distressed on oxygen nasal canula with no pallor or jaundice. The Vital signs were Bp 87/57, pulse 41, RR 28, temp 37.2, and sat 95 % on oxygen nasal canula. The abdominal examination revealed tenderness over epigastric and right hypochondrial areas. It also showed limbing of right loer limb as an old sequale of rheumatoid arthritis with no more other deformities. The chest examination was unremarkable.

2.1.3 History of past illness

The patient has been suffering from hypothyroidism and rheumatoid arthritis other than the liver cysts (misdiagnosed as simple ones). The patient is receiving levothyroxine 100mcg/day for hypothyroidism and

Plaquenil 200mg/day for rheumatoid arthritis. The patient had a history of laparoscopic sleeve gastrectomy nine months ago for BMI=44 with limbing (weight =98kg, height=148cm).

2.1.4 Laboratory examinations

The laboratory analysis results were ALT, 13 (5-45 U/L); AST, 11 (5-45 U/L); total bilirubin, 1.1 (0.2-1.2 mg/dL); ALP, 75 (40-150 U/L); and GGT, 35(9-48 U/L). CBC results: 31000/ml white blood cells (neutrophils 86%, eosinophils 0.8%)

2.1.5 Imaging examinations

Routine preoperative abdominal US was done before sleeve gastrectomy and showed three liver cysts which had been described as simple ones at that time (Figures 1). Contrast-enhanced abdominal computed tomography (CT) was done 6 months post-sleeve gastrectomy showing three uncomplicated cysts (Figure 2). The abdominal US and abdominal CT with IV contrast were done at the time of emergency admission and showed that The right lobe of the liver has three multiple cystic lesions with multiple hydatid cysts (size of the largest cyst: 50 mm x 45 mm x 38 mm) that were associated with mild to moderate peritoneal effusions. This result was compatible with a perforated hydatid cyst with free peritoneal fluids as seen on abdominal CT scans (Figures 3).

Figures 1; Abdominal us showed three liver cysts (described as simple ones).

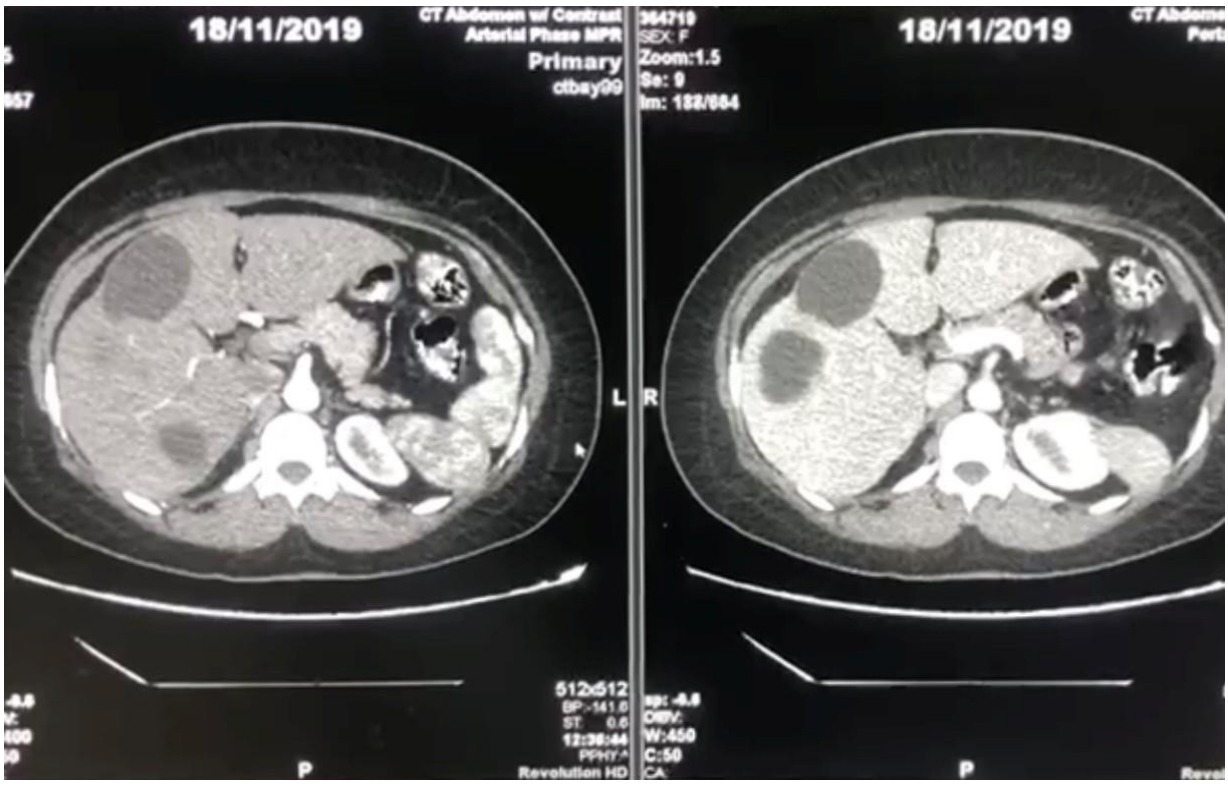

Figure 2; Abdominal CT with contrast shows three hydatid cysts in the right lobe of the liver.

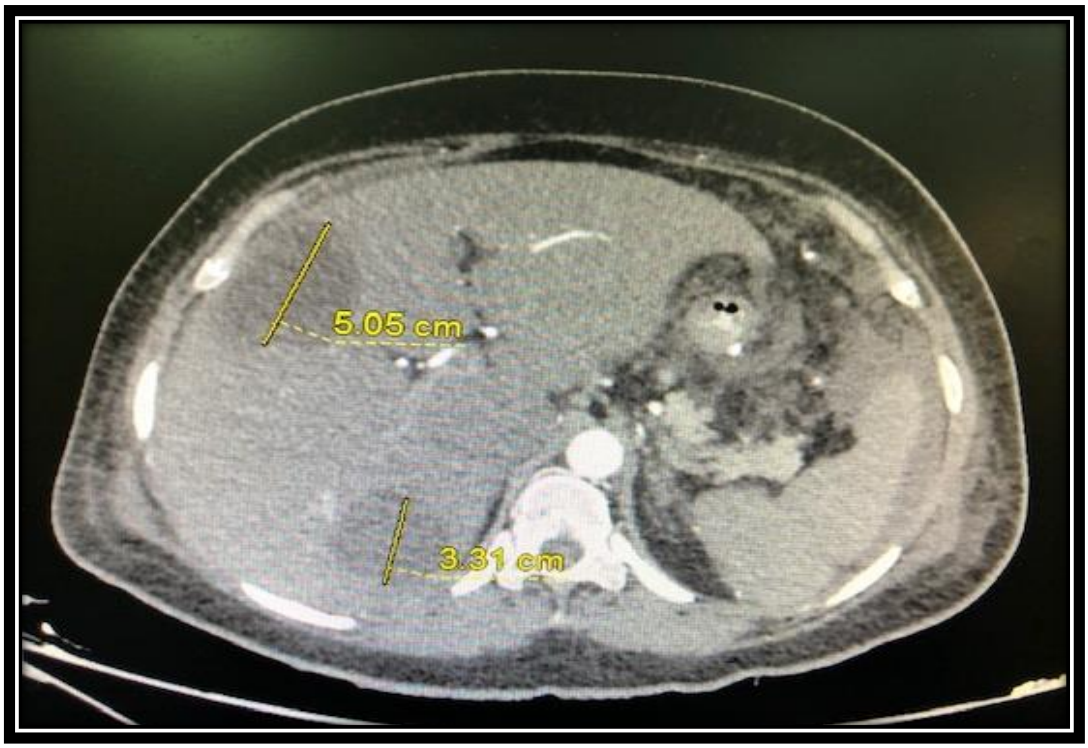

Figure 3; Abdominal CT with contrast shows that free fluid is adjacent to the cyst which is compatible with ruptured hydatid cyst with free peritoneal fluids.

3. FINAL DIAGNOSIS

Intraperitoneal perforation of hydatid cyst of the liver with generalised peritonitis.

4. TREATMENT

Antihistaminic, corticosteroid, inotropic and fluid resuscitation treatment was promptly started at the ICU. she received inotropic support (norepinephrine0.2 mcg), iv fluid, and iv antibiotics (Imipenem 1g iv TID-Flagyl 500mg iv TID). Analgesia was given regularly eg paracetamol 1g IV TID.Tablets Of Albendazole 400 mg had been given PO BID 2 days before surgery, In addition to; Omeprazole 40 mg IV OD, Clexane 40 mg SC OD, Hydrocortisone 100mg IV q 6 hours, and Thyroxine 100 mcg PO OD.

Laparoscopy was conducted depending on the general status of the patient. Intraoperatively, there was a large amount (2500 mL) of free fluid containing contents of the cyst mixed with pus. After aspiration, after irrigation with hypertonic saline solution 3%, the peritoneum was washed extensively with normal saline. Total cystectomy with proper drainage of abdominal and cystic cavities was performed during the completion of the surgery (figures 6, 7&8). Nothing was done for the uncomplicated liver cysts at this urgent surgical session but, they had been excised after 16 months electively.

Figure 4; Intraoperative appearance of dirty free fluid in the pritoneal cavity secondary to intra- peritoneal rupture ofhepatic hydatid cyst.

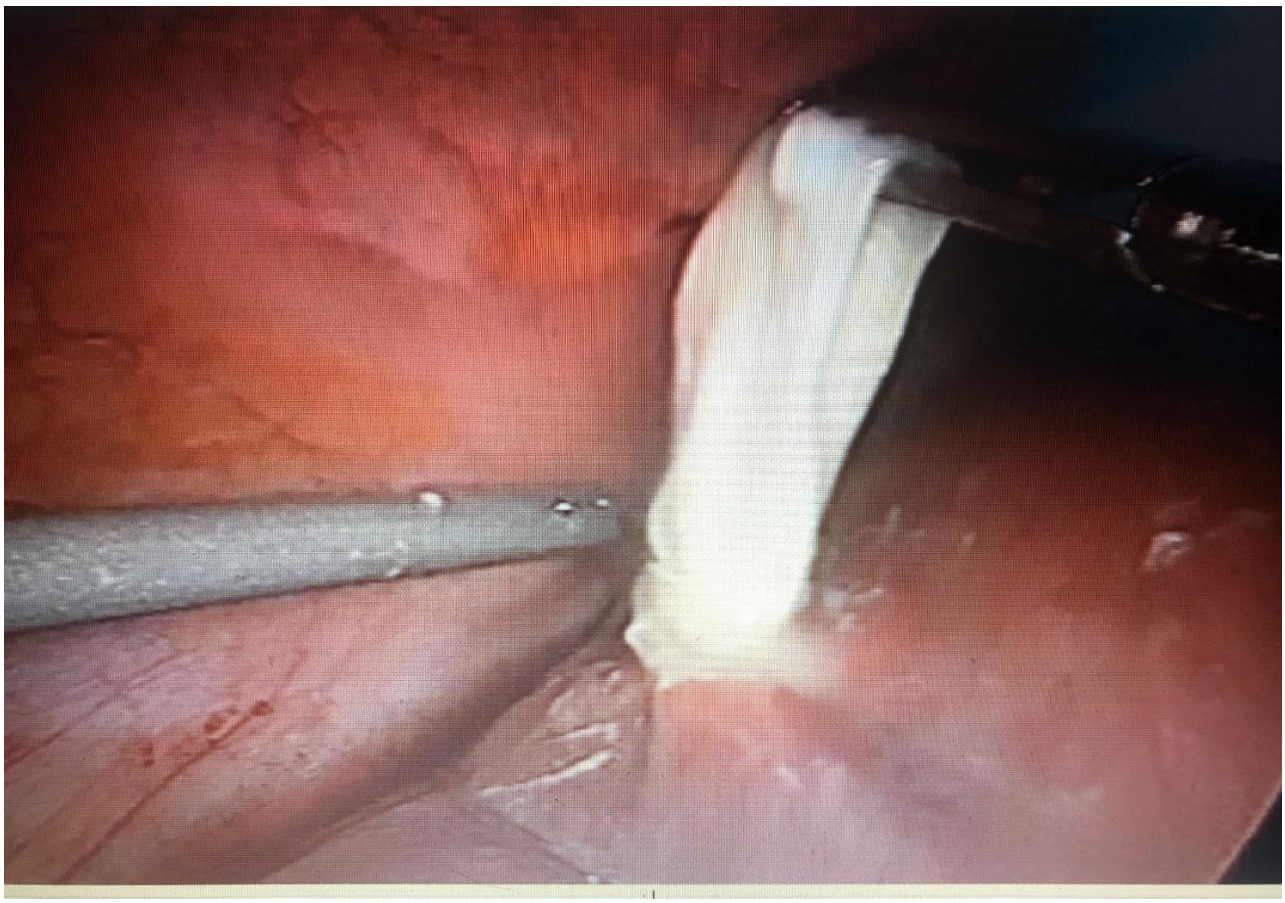

Figure 5; Intraoperative image obtained during avulsion of the hydatid cyst from its cavity, after evacuation of the cystic contents.

5. OUTCOME AND FOLLOW-UP

The women dramatically improved (clinically & laboratory) in the postoperative period and discharged home after 5 days (2 days ICU, 3 days ward). Three cycles(cycle=4-wk) of albendazole treatment were planned and started as specific antihelminthic chemotherapy for 2-wk with 2-wk free intervals, in addition to the chronic therapy mentioned before. No postoperative complications were recorded either early or late till 22 months follow up. Follow up abd. us showed no residual remnants of the previously complicated cyst with no significant changes of the other uncomplicated ones till their removal 5 months ago.

6. DISCUSSION

6.1 Incidence of complications

Various complications can occur for about 5%-40% of the patients with hepatic hydatid cysts and other organs. These complications related to hydatid cysts include superinfection, rupture into the adjacent organs (bronchopleural fistula, broncho-biliary fistula, intrapleural rupture, venae cava, intrapericardial rupture and intraperitoneal rupture), allergic reactions, gastric outlet obstruction, portal hypertension (pre- hepatic, hepatic, post-hepatic), cirrhosis, membranous glomerulonephritis and Budd Chiari syndrome (compression on hepatic veins) [1], [3], [7], [9]. Morbidity rate after intraperitoneal perforatoin is 10-35.3% and the mortality rate is 23.5%, in the medical reviews [7], [9]. Intraperitoneal perforation of the hydatid cyst is the third most frequent complication (0.9%-16%) after allergic reactions (1%-25%) and intrabiliary rupture (5%-25%) [4], [7]. Intraperitoneal perforation may occur spontaneously due to intracystic pressure elevation or result from trauma including iatrogenic one during routine surgery [10], [11], [40].

6.2 Common risk factors for perforation

-Size of the cyst

It is possible that the cysts grow to 5 – 10 cm in size or longer and may last for decades. During the growth phase of the cyst (> 10 cm), perforation can occur when the pressure inside the cyst (intracystic pressure >50 cmH2O) is more significant than the resistance of the wall of the cyst (pericyst) with the increase of spontaneous or traumatic rupture risk. Finally, the complications are only the consequence of the rupture [1], [6], [10], [41].

-The superficial localization

The superficial cyst is not protected sufficiently by hepatic parenchyma, so the superficial localization can be considered as a facilitator for perforation of the cyst [1], [4], [45].

-The age and trauma

Complications including rupture are more common in adults than elders as they are more active in daily life with frequent exposure to the trauma of different intensities and traffic accidents [13], [50].

-The weight loss and hydatid cyst

Weight loss can be a non-specific signs of hydatid cyst due to loss of appetite, weakness, vomiting, and abdominal pain [17], [50]. Patients can expect significant decreases in liver volume, regression of hepatic steatosis, and decreases in visceral adiposis at 6 months after bariatric surgery [14]. In our point of view, we consider that significant weight loss of our case report (post- Bariatric Surgery) is an important contributing risk factor for hydatid cyst rupture (Very little if any is written about that) due to changes after bariatric surgery affecting liver volume and fat the density with the following possible reasons for rupture;

- Attenuated or absent protective hepatic parenchyma over the cyst with superficial localization.
- Relative reduction of the liver support due to diminished fatty cushion of the visceral adiposis reduced liver volume, and subsequent laxity of hepatic ligamentous support.
- Rising stress forces on the cyst wall which is resulting from reduced liver volume with progressive growth of the cyst and regression of hepatosteatosis.

6.3 Clinical picture of intraperitoneal cyst rupture

It is widely variable presentations and durations with a sudden or gradual onset. Patients may have one or more of the following clinical presentations.

6.4 Gastrointestinal manifestations

Mild or severe abdominal pain, vomiting, nausea, and diarrhea are the most frequent symptoms. Peritoneal irritation and acute abdomen can occur due to the cystic contents especially if purulent or associated with bile [1], [4], [13].

6.5 Immunologic manifestations

They are a wide spectrum of presentations that may develop ranging from minor allergic reactions (16.7%-25% of patients), such as urticaria, fever, asthma, eosinophilia and macular eruption up to life- threatening severe allergic reactions (1%-12.5%) such as peripheral edema, syncope, respiratory distress and anaphylaxis is due to the cyst content (antigenic fluid), which rupture into the celomic cavity or occur after direct communication with the systemic circulation (absorbed into the circulation) or occur when it communicates with the biliary tract spontaneously or following trauma (including iatrogenic one) [6], [18].

Some patients can develop anaphylactic reactions during cyst surgery (0.2%-3.3%) with no experience of rupture [1], [10], [11], [39].

6.6 Diagnostic investigations

6.6.1 Imaging investigations

US is the most common bedside diagnostic tool with 85% sensitivity which can be done intra- operatively. Doppler US and Endoscopic US (EUS) can be used as diagnostic tools. Contrast-enhanced CT can be used in patients with hemodynamic stability giving results up to 100% of sensitivity [9], [15], [34]. Also, MRI, combined with case history can be used. 20%–30% of hydatid cysts can be manifested in plain radiographs by non-specific patterns of calcification of the pericyst or an elevation of hemidiaphragm. Endoscopic retrograde cholangiopancreatography can be very useful if communication with the biliary tree is suspected giving the chance of its using as therapeutic tool simultaneously [8], [12], [35].

6.6.2 Serology and immunological investigations [18], [36]

ELISA can be used for liver cysts (80-100% sensitive) in mass scale screening. With false positive reaction in persons with chronic immune disorders, cancer, or other tapeworm infections. Seronegative Patients occur when having senescent, calcified, or dead cysts. The counter-immuno-electrophoresis has the highest specificity (100%) and high sensitivity (80 – 90%). Indirect immunofluorescence assay (IFA) in patients with hepatic hydatid cyst has the highest sensitivity (95%). Casoni test is only of historical importance due to low sensitivity. Fine needle biopsy is contra-indicated to avoid leakage with subsequent anaphylactic reactions and secondary hydatidosis.

6.6.3 Different modalities of treatment

Chemotherapy in conjunction with surgery (open or laparoscopic) are highly efficient tools in management of hydatid disease and in prophylaxix against local recurrence and secondary hydatidosis. PAIR technique is a safe effective tool in treatment of selective patients which can be used as an alternative to surgery in some situations. Sometimes no treatment is needed [19], [20], [37], [38].

6.6.4 The aims of surgical treatment

They include;

- In the early term of emergent condition, reduction or prevention of the anaphylactic reactions.
- Inactivation of the parasite, evacuation of the cyst content with resection of the germinal layer, and obliteration of the residual cavity.
- Prevention of the development of secondary hydatidosis or recurrence on long-term outcome [7], [21], [38]

Surgical pathology of hydatid cyst; The primary cyst is composed of:

1. Adventitia layer (pericyst); of compressed liver parenchyma and fibrosis and it is important for pericystectomy.
2. Laminated membrane (ectocyst) which is elastic white easily separable layer from the adventitia.
3. Germinal epithelium (endocyst) – is the only living lining of the cyst which is responsible for reproduction of daughter cysts and for recurrence if left in place with incomplete removal [22], [46], [50].

Principles of surgical management of hydatid cyst rupture; [23], [24], [46], [49].

- After confirmation of the intraperitoneal rupture, the antihelminthic treatment should be started as rapid as possible at the surgery departement and to be resumed after surgery to reduce the mortality and morbidity due to overlooked cystic contents during surgery.

- Surgical management is the gold standard treatment for hepatic hydatid disease.
- Stabilization of the patient hemodynamic status by aggressive medical treatment is an essential preparatory step to urgent surgery which should be undergone as soon as possible.
- Surgical approach should be tailored carefully in accordance with general principles of surgery. Laparoscopic or open surgery can be conducted for hemodynamically stable patients, but unstable ones are reserved for open surgery.
- Urgent removal of the cyst content outside the abdomen is the crucial step to stop triggering of anaphylactic reactions [5], [7], [50].
- Appropriate peritoneal lavage should be done (at least two times 10 min apart for 10-15 min possible) with proper local scolicidal agents like hypertonic saline (3%-10%-15), chlorhexidine, povidone iodine (10%-50%), and others [22], [38].
- Careful examination of the cyst for the remnants of the contents or the wall and for communication and relationship of the surrounding structures and the cyst such as leakage test which is performed via saline administration through the cystic duct/common bile duct to check the communication between the biliary tree and the cyst.
- The residual cavity should be managed by any one of the different methods like; external tube drainage, omentoplasty (isolated or pedicled) or capitonnage [22], [49].
- Spleen preservation techniques should be preferred if the spleen is contracted [5].
- The abdominal and the cystic cavities should be adequately drained with suitable drains after completion of the surgical procedure [22], [50].

6.7 Surgical approaches

6.7.1 Radical procedures

These procedures may include cystectomy, pericystectomy, lobectomy, or hepatectomy. They carry a lower risk of complications and recurrence, but some researchers are considering pericystectomy, lobectomy, and Hepatectomy of high intra-operative risks for benign pathology [22], [24], [46]. A closed cyst resection is a safe and effective treatment option for LHD with a low recurrence rate. As recurrence could occur after 10 years, a patient's follow-up should be adapted for this circumstance [46], [49].

Cystectomy =removal of the germinal and laminated layers.it is safe and simple one with low rate of complication.
Pericystectomy=cystectomy+resection of compressed liver tissues and fibrosis.it has lower risk of recurrence but with considerable blood loss and hazardous in complicated giant cyst.
Lobectomy and hepatectomy=non anatomical resection which is risky operations for benign conditions.

6.7.2 The conservative surgical technique

The most common used procedure was Marsupialization .it is a safe, simple, and quick procedure for uncomplicated cyst but has a high rrate of postoperative complications (4%-28%) such as bile leak and biliary peritonitis [22].

6.7.3 Additional operative procedures (to be done once needed); [22], [25], [32], [48]

- Primary repair of bile duct orifice with placement of T-tube for high flow output fistula.
- ERCP visualization and stenting of CBD can be selected as an alternative tool for T-tube.
- An endoscopic sphincterotomy may also be performed to facilitate drainage of the common bile duct.

6.7.4 Laparoscopic approach

The feasibility of laparoscopic surgery has been confirmed by several reports [22]. In the treatment of liver hydatid cysts, no significant differences have been found between open surgery and laparoscopic surgery. Nevertheless, informative measurements could be calculated for complications, recurrence, mortality, and cure rates based on these surgeries [44].

Advantages of laparoscopy are [20], [44].

- a lower outcome of morbidity
- a shorter length of hospital stay.
- a faster recovery of surgery.
- a better visualization of the cavity under laparoscopic magnification giving a better chance of detection of any biliary communication.

Disadvantages of laparoscopy; [20], [44].

- lack of the measures to prevent spillage of the cystic cotents under the high pressure of pneumoperitoneum,
- with high incidence of allergic reactions due to peritoneal spillage.

The exclusion Criteria of laparoscopy; [20], [44].

- cysto-biliary fistula with bile leak.
- The hydatid cyst of Central location
- Giant cysts with > 15 cm diameter
- The cysts are > 3 in number
- Calcified or thickened walls

Percutaneous treatment =PAIR (puncture - aspiration - injection - respiration) [19], [26], [38], [42], [43].
It is an US guided procedure that first used in 1986 by the Tunisian team. The World Health Organization (WHO) recommends PAIR as a safe alternative to surgery.

Guidelines of WHO for of PAIR (indications, contraindications, and Prerequists);

1. Indications for PAIR;

Nonechoic lesion if the diameter is ≥5 cm
Cysts with presence of multiple daughter cysts and/or with detached membrane Many cysts localised in several organs Infected cysts Refusal of surgery Relapse after surgery Inadequate surgical facilities
Presence of contraindication of surgery Failure of chemotherapy alone Pregnant women Children ≥ 3 years

2. Contraindications for PAIR

Uncooperative persons Risky or unaccessible sites Cysts in heart, brain, and/or spine Inactive or calcified lesion Cysto-biliary fistula

3. Prerequists of PAIR;

- Highly specialized centers with experienced staff
-An anaesthiest for monitoring and management of anaphylaxis
- Immediate notification of Surgeons in case of complication [19].

Chemotherapy for hydatid disease of liver [27], [28], [47]
Rationale of Medical treatment;
It, primarily started in the 1970's, is based on mebendazole and albendazole Clinical evidence of a reduction in cyst size was based on the drug's ability to penetrate the cyst wall and its ability to maintain

therapeutic levels of the active metabolites.
Albendazole (10-15 mg/kg per day) is more effective and preferred due to better penetration and absorption. These agents lead to reduction of the cyst size or its stabilization, especially in cases with small cysts. Disseminated systemic disease, inoperable cases, and postoperative recurrence prevention when combined with surgery are some of the conditions for which they are used. The treatment should last between 1 and 12 mo, according to the literature recommendation [7].

Albendazole has the following side effects;
Alopecia, rash, dizziness, pruritis, mild abdominal pain, nausea, vomiting, nausea and headache.
Rarely, leucopenia, eosinophilia, icterus, and mildly elevated transaminase levels are seen.
The different schedules for the treatment are: [19], [47]

1. Inoperable cases - as primary treatment - 3 cycles
2. pre-operatively – to reduce the risk of recurrence 6 weeks continuous treatment
3. post-operatively to prevent recurrence in cases of intraoperative cyst spillage 3 cycles.

6.8 Conservative treatment

Sometimes no treatment is needed. But the infected person will need a long period of time to be monitored. No probable surgery but only a 'watch and wait' approach, for the cysts with homogeneous calcification of the walls [19], [47].

6.9 Outcome of different therapeutic modalities

6.9.1 Outcome of therapeutic modalities

Surgery can be performed successfully in 90% of patients if a cyst has accessible localisation [49]. PAIR plus albendazole have high safety and efficacy in treatment of selected patients. [29] reported 88% eradication of cysts with PAIR which was preceded for 8 weeks by Albendazole therapy. In his study, the efficacy of PAIR is like that of cystectomy with standard chemotherapy by reduction of the cyst size and causing its eradication over 2-year duration. In a review by [30], Based on the results, the level of evidence for choosing between conservative or radical treatment was too low, since medical treatment is not the optimal therapy for uncomplicated hepatic hydatid cysts when used alone.

Morbidity outcome: Bile leak is the most common complication postoperatively (6 - 28%). Endoscopic sphincterotomy can be done in low-flow fistulas after a 3-week waiting duration or earlier in high-flow fistulas. [31,48] Infection of the residual cavityof big hydatid cysts and treated by partial cystectomy. This may necessate percutaneous CT guided drainage or reoperation if needed. Recurrence rate (0-28%) is variable according to type of surgery; it may be 11.3 % within 5 years [6], [7], [9], [47].

Mortality outcome: The surgical management carries about 0.9 to 3.6 % of mortality rate [32].

6.9.2 Clinical follow- up

It should be more frequent for complicated hydatid cyst patients than ones without complications. follow-up should be done Regularly during the early period, once in a month and in the long-term, once a year. Recurrence is increasing in more complicated cysts especially whose daughter cysts. Clinical follow- up should be regularly after either PAIR or surgical treatment. US, CT, and immunological assays can be selected during follow-up. Follow-up can be terminated if there is no recurrence after 5 years [19], [32], [36].

7. Conclusion

Perforation of the hydatid cyst into the peritoneum, is a rare severe life-threatening condition causing deleterious hemodynamic instability and anaphylactic reactions. So, perforation of the hydatid cyst should be in mindof physians as a differential diagnosis in patients whose acute abdomen with allergic reactions. Parameters of hemodynamic instability, due to anaphylaxis, should be corrected promptly, so that the emergent surgical intervention can save the patient's life. We consider that significant weight loss (post-Bariatric Surgery) is an important contributing risk factor for hydatid cyst perforation due to considerable changes after bariatric surgery affecting liver volume and fat density.

8. References

[1] Moro P, Peter M S. Echinococcosis: a review.Int J Infect Dis 2009; 13: 125-33

[2] Nunnari G, Pinzone M R, Gruttadauria S, Celesia B M, Madeddu G, Malaguarnera G, et al.Hepatic echinococcosis: Clinical and therapeutic aspects. World J Gastroenterol 2012; 18(13): 1448-1458

[3] Akbulut S. Parietal complication of the hydatid disease: Comprehensive literature review. Medicine (Baltimore) 2018; 97: e10671

[4] Toumi O, Noomen F, Salem R, Rabeh H, Jabra SB, Korbi I, Bannani S, et al. Intraperitoneal rupture of hydatid cysts. Eur J Trauma Emerg Surg 2017; 43: 387-391

[5] Belli S, Akbulut S, Erbay G, Koçer NE. Spontaneous giant splenic hydatid cyst rupture causing fatal anaphylactic shock: a case report and brief literature review. Turk J Gastroenterol 2014; 25: 88-91

[6] Unalp HR, Yilmaz Y, Durak E, Kamer E, Tarcan E. Rupture of liver hydatid cysts into the peritoneal cavity. A challenge in endemic regions. Saudi Med J 2010; 31: 37-42

[7] Tinsley B, Abbara A, Kadaba R, Sheth H, Sandhu G. Spontaneous intraperitoneal rupture of a hepatic hydatid cyst with subsequent anaphylaxis: a case report. Case Reports Hepatol 2013; 2013: 320418

[8] İlhan Çiftçi, Hüseyin Yılmaz. Hepatic Hydatid Cyst and Intraperitoneal Free Hydatid Cyst. Eur J Gen Med 2012;9 (Suppl 1):50-52

[9] Mouaqit O, Hibatallah A, Oussaden A, Maazaz K, Taleb KA. Acute intraperitoneal rupture of hydatid cysts: a surgical experience with 14 cases. World J Emerg Surg 2013; 8: 28

[10] Malik AA, Bari SU, Amin R, Jan M. Surgical management of complicated hydatid cysts of the liver. World J Gastrointest Surg 2010; 2: 78-84

[11] Karakaya K. Spontaneous rupture of a hepatic hydatid cyst into the peritoneum causing only mild abdominal pain: a case report. World J Gastroenterol 2007; 13: 806-808

[12] Erel S, Kilicoglu B, Kismet K, Gollu A, Akkus MA. Peritoneal hydatid cyst perforation: a rare cause of emergency abdominal surgeries. Adv Ther 2008; 25: 943-950

[13] Kemal Karakaya. Spontaneous rupture of a hepatic hydatıd cyst into the peritoneum causing only mild abdominal pain: A case report. World J Gastroenterol February 7, 2007; 13(5) :806-8

[14] Luo R B, Suzuki T, Hooker J C, Covarrubias Y, Schlein A, Liu S. How Bariatric Surgery Affects Liver Volume and Fat Density in NAFLD Patients.Surg Endosc. 2018 Apr;32(4):1675-1682

[15] F. Castro-Poças,Tarcísio Araújo, André Coelho, Donzilia Silva, Isabel Pedroto. Hydatid Cyst Diagnosed by Endoscopic Ultrasound.Can J Gastroenterol Hepatol. 2016; 2016:7260392

[16] Heymann DL.Control of Communicable Diseases Manual. (20th edition). Washington, DC: American Public Health Association (2015), pp178 - 83.

[17] World Health Organisation. Echinococcosis fact sheet full article 23 march 2020. https://www.who.int/news- room/fact-sheets/detail/echinococcosis

[18] Wenbao Zhang, Hao Wen, Jun Li, Renyong Lin, Donald P. McManus. Immunology and Immunodiagnosis of Cystic Echinococcosis: An Update. Clin Dev Immunol. 2012; 2012: 101895

[19] Antonio Giorgio, Antonella Di Sarno, Giorgio de Stefano, Giulia Liorre Nunzia, Farella Umberto Scognamiglio, Valentina Giorgio. Sonography and Clinical Outcome of Viable Hydatid Liver Cysts Treated with Double Percutaneous Aspiration and Ethanol Injection as First-Line Therapy: Efficacy and Long-Term Follow-Up- AJR 2009; 193:186–92

[20] Hesham Maged Hasan, Osama Mahmoud El-Sayed. Laproscopic treatment of liver hydatid cyst. Journal of Medicine and Biomedical Sciences, May, 2010

[21] Bennett, J., Dolin, R., Blaser, M., Mandell, G. & Douglas, R. Mandell, Douglas, and Bennett's Principles and Practic e of Infectious Diseases,2014(8th edition). Philadelphia, PA: Elsevier/Saunders.

[22] Fethi Derbel, Mohamed Ben Mabrouk, Mehdi Ben Hadj Hamida,and Jaafar Mazhoud. Hydatid Cysts of the Liver – Diagnosis, Complications and Treatment. intechopen.com/books/2012/abdominalsurgery/chapter5, p107-38

[23] Zaouche A, Haouet K. Traitement chirurgical des kystes hydatiques du foie. EMC, Techniques chirurgicales, Appareil digestif. Elsevier Masson; 40-775

[24] Balik A A, Başoğlu M, Celebi F, Oren D, Polat K Y, Akçay M N. Surgical Treatment of Hydat Disease of the Liver: Review of 304 Cases. Arch Surg. 1999; 134:166-69

[25] Ersan O, Yusuf B. Endoscopic therapy in the management of hepatobiliary hydatid disease. J Clin Gastrienterol 2002; 35:160-74

[26] World Health Organization. PAIR: Puncture, Aspiration, Injection, Re-Aspiration- An option for the treatment of Cystic Echinococcosis. WHO/CDS/CSR/APH/2001.6

[27] Aktan AO, Yalin R. Preoperative albendazole treatment for liver hydatid disease decreases the viability of the cyst. Eur J Gastroenterol Hepatol. 1996; 8:877-9

[28] Blanton RE, Wachira TM, Zeyhle EE, Njoroge EM, Magambo JK, Schantz PM. Oxfendazole treatment for cystic hydatid disease in naturally infected animals. Antimicrob Agents Chemother. 1998;

42:601-605

[29] Khuroo MS, Wani NA, Javid G, Yattoo G N, Shah A H, Jeelani S G. Percutaneous drainage compared with surgery for hepatic hydatid cysts. N Engl J Med 1997; 337:881–7

[30] ziri C, Haouet K, Fingerhut A. Treatment of hydatid cyst of the liver: where is the evidence? World J Surg 2004; 28:731–6

[31] Skroubis G, Vagianos C, Polydorou A, Tzoracoleftherakis E, Androulakis J. Significance of bile leaks complicating conservative surgery for liver hydatidosis. World J Surg.2002; 26:704-8

[32] Sami Akbulut and Fatih Ozdemir. Intraperitoneal rupture of the hydatid cyst: Four case reports and review of literature. World J Hepatol. 2019 Mar 27; 11(3): 318–29

[33] Gavara C G i, López-Andújar R, Ibáñez T B, Ángel J M R, Herraiz A M, Castellanos F O, et al. Review of the treatment of liver hydatid cysts. World J Gastroenterol. 2015 Jan 7; 21(1): 124–131

[34] J. C. Liem. Focal cystic liver lesions differentiated based on radiological imaging findings. EPOS poster ECR 2012. Poster No.: C-2147.

[35] Rabii Noomene, Anis Ben Maamer, Ahmed Bouhafa, Noomen Haoues, Abdelaziz Oueslati, Abderraouf Cherif. Primary Hydatid Cyst of the Gallbladder: An Unusual Localization Diagnosed by Magnetic Resonance Imaging (MRI). Pan Afr Med J. 2013; 14:15

[36] Nunnari G, Pinzone MR, Gruttadauria S, Celesia BM, Madeddu G, Malaguarnera G, et al. Hepatic echinococcosis: Clinical and therapeutic aspects. World J Gastroenterol 2012; 18:1448-1458.

[37] Akkucuk S, Aydogan A, Ugur M, Yetim I, Davran R, Oruc C, et al. Comparison of surgical procedures and percutaneous drainage in the treatment of liver hydatide cysts: a retrospective study in an endemic area. Int J Clin Exp Med 2014; 7:2280-2285.

[38] Georgios K. Georgiou, Georgios D. Lianos, Avrilios Lazaros, Haralampos V. Harissis, Alberto Mangano, Gianlorenzo Dioni gi,Christos Katsios. Surgical management of hydatid liver disease. Int J Surg. 2015 Aug; 20:118-22

[39] Rinaldi F, Brunetti E, Neumayr A, Maestri M, Goblirsch S, Tamarozzi F. Cystic echinococcosis of the liver: A primer for hepatologists. World J Hepatol 2014; 6:293–305

[40] Touma D, Serste´ T, Ntounda R, Mulkay J, Buset M, Laethem Y V. The liver involvement of the hydatid disease: a systematic review designed for the hepato gastroenterologist. Acta Gastroenterol Belg 2013; 76:210–8

[41] Giorgio A, Calisti G, de Stefano G, Farella N, Scognamiglio U, Giorgio V. Percutaneous treatment of hydatid liver cysts: an update. Recent Pat Antiinfect Drug Discov 2012; 7:231–6

[42] Anand S, Rajagopalan S, Mohan R. Retraction notice to "Management of liver hydatid cysts - Current perspectives" [Medical Journal Armed forces India 68 (2012) 304-309] [retraction of: Med J Armed

Forces India. 2012 Jul;68(3):304-9]. Med J Armed Forces India

[43] Köroğlu M, Erol B, Gürses C, Turkbey B, Bas C U, Alparslan A S. Hepatic cystic echinococcosis: percutaneous treatment as an outpatient procedure. Asian Pac J Trop Med. 2014;7(3):212-215

[44] Massoud Sokouti, Ramin Sadeghi, Saeid Pashazadeh, Saeed Eslami Hasan Abadi , Mohsen Sokouti , Peyman Rezaei-Hachesu ,et al.A Systematic Review and Meta-Analysis on the Treatment of Liver Hydatid Cyst: Comparing Laparoscopic and Open Surgeries.Arab J Gastroenterol. 2017 Sep;18(3):127-135

[45] Eylul Gun, Demet Etit, Dilara O Buyuktalanci, Fulya Cakalagaoglu. Unusual Locations of Hydatid Disease: A 10- year Experience From a Tertiary Reference Center in Western Turkey. Ann Diagn Pathol. 2017 Aug; 29:37-40

[46] Pang Q., Jin H., Man Z., Wang Y., Yang S., Li Z., et al. Radical versus conservative surgical treatment of liver hydatid cysts: a meta-analysis. Front Med. 2017:669–75

[47] Kern P., Menezes da Silva A., Akhan O., Müllhaupt B., Vizcaychipi KA., Budke C., et al. The Echinococcoses: Diagnosis, Clinical Management and Burden of Disease. Adv Parasitol. 2017; 96:259-369

[48] Lv H., Jiang Y., Peng X., Zhang S., Wu X., Yang H., et al. Subadventitial cystectomy in the management of biliary fistula with liver hydatid disease. Acta Trop. 2015Jan;141(PtB):223-8. https://doi.org/10.1016/j.actatropica.2014.06.006

[49] Julien, C., Le Treut, Y.P., Bourgouin, S., Palen A, Jean H. Closed Cyst Resection for Liver Hydatid Disease: a New Standard. J Gastrointest Surg (2020). https://doi.org/10.1007/s11605-019-04509-1

[50] Mehmet Mihmanli, Mert Tanal, Emre Bozkurt and Onur Guven. The Surgical Management of Hydatid Cyst of the Liver: What is New? Overview on Echinococcosis, (January 4th 2020). Fethi Derbel and Meriem Braiki, IntechOpen, DOI: 10.5772/intechopen.90726. Available from: https://www.intechopen.com/books/overview-on- echinococcosis/the-surgical-management-of-hydatid-cyst-of-the-liver-what-is-new-