

# Primary treatment and prognosis in 15 cases with stage IVB cervical cancer

Kanda, R.<sup>1\*</sup>, Nagasaka, K.<sup>1</sup>, Sugihara, T.<sup>1</sup>, Ryo, E.<sup>1</sup>, Ayabe, T.<sup>1</sup>

Department of Health Informatics, Rutgers, The State University of New Jersey, USA<sup>1</sup>

Corresponding author: 1\*



---

**Keywords:**

Hand infection,  
Rehabilitation, Surgery, Hand  
based splint

---

---

**ABSTRACT**

When initial treatment and rehabilitation are inappropriate, it may leave severe dysfunction in hand infection. We experienced rehabilitation with postoperative hand based splint therapy and obtained good results. Case 1 A 59-year-old male stuck chopsticks in the right-hand metacarpus, the middle of the left volar hand was painful. The post-operative rehabilitation conducted blocking exercise and adductor stretching. There are not the pain and excursion restrictions. Case 2 A 64-year old male was operated for purulent flexor tendon tenosynovitis. The postoperative rehabilitation was done in the same method and there are not the pain and excursion as Case 1. Enforcement of careful exercise therapy depending on an episode of care is important.



This work is licensed under a Creative Commons Attribution Non-Commercial 4.0 International License.

---

## 1. INTRODUCTION

When initial treatment and a postoperative after care are inappropriate for the inflammatory disorder of the finger, we may leave dysfunction. We gave surgery and postoperative splint therapy, rehabilitation, and we obtained good results for the supportive myelitis of the finger and purulent flexor tendon tenosynovitis.

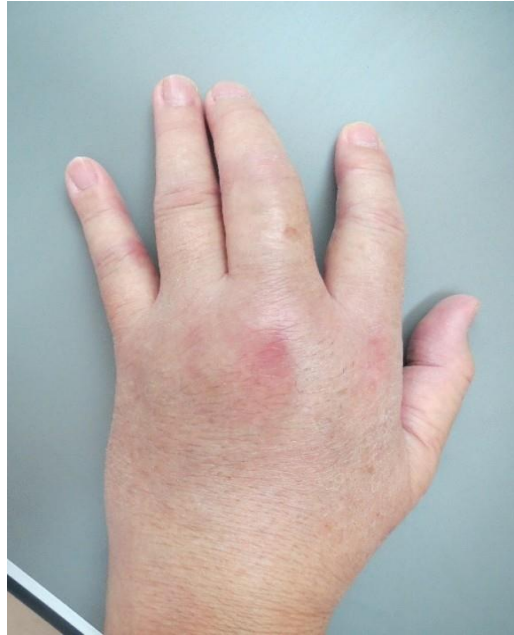## 2. CASE PRESENTATION

### 2.1 Case 1

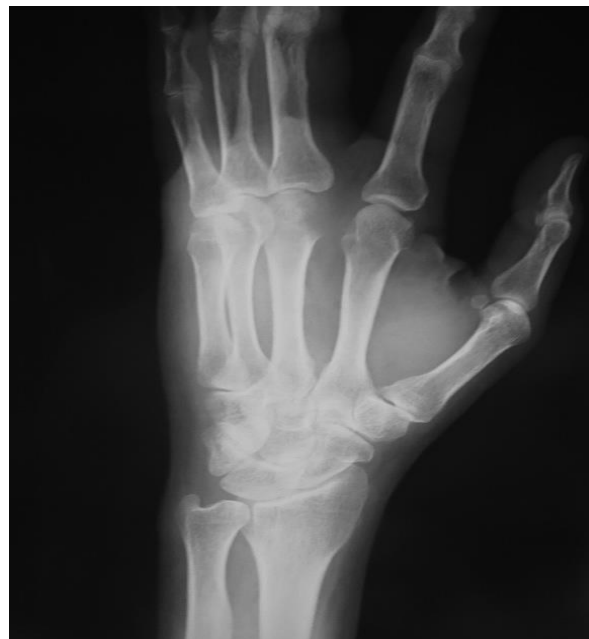A 59-year-old male stuck chopstick in the right hand metacarpus, and treated in other hospitals, but came to this hospital because a pain and swelling, the flexure disorder of the finger was not improved. The middle of the left volar hand was painful and was enlarged to the dorsal side, and it was approximately impossible to flex a middle finger (Figure 1). A part of the middle finger metacarpal head had a bone fusion image by the X-rays and was high intensity with a T2- image by the MRI (Figures 2(a) and 2(b)). Subcutaneous tissue showed pus by the surgery, and there was a fistula in the metacarpal neck (Figure 3). The post-operative rehabilitation conducted blocking exercise and adductor stretching from 2 days after surgery. It started than weak power of traction using hand based splint from one week after surgery and gradually lengthened wearing time (Figure 4). The pain and excursion restrictions returned to work to cry in one year after surgery.

## 2.2 Case 2

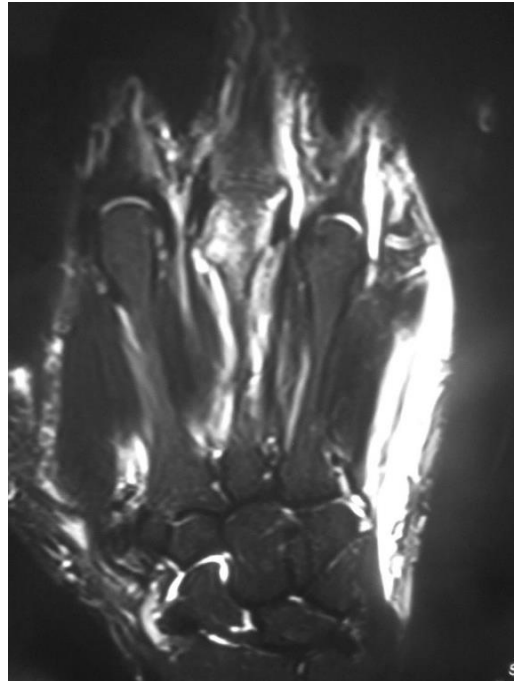
A 64-year old male was treated with swelling of fingers and excursion restrictions in the right in other hospitals. Because swelling was not improved, he consulted our hospital. The right middle finger was swelling and extended to the dorsal side. There was inflammation along a tendon sheath in the right by the surgery and it was eliminated and washed site of inflammation (Figure 5). Excursion restrictions and the swelling are improved, and ADL (activity of daily living) does not have any problem.



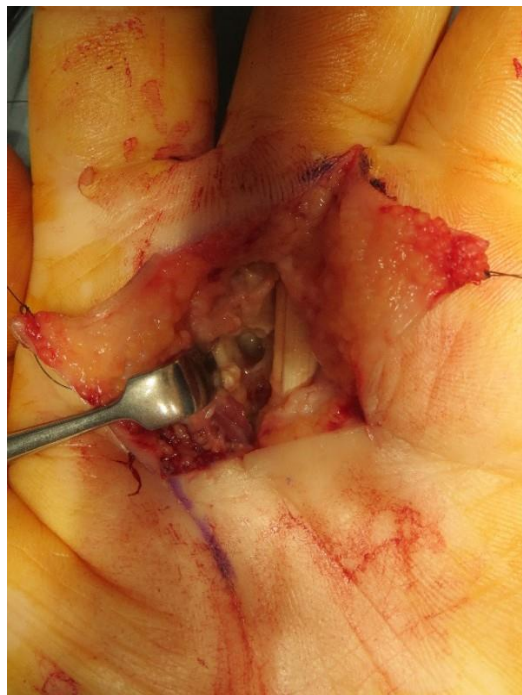**Figure 1.** Initial presentation of case 1: The middle of the left volar hand was enlarged to the dorsal side, and it was impossible to flex a middle finger



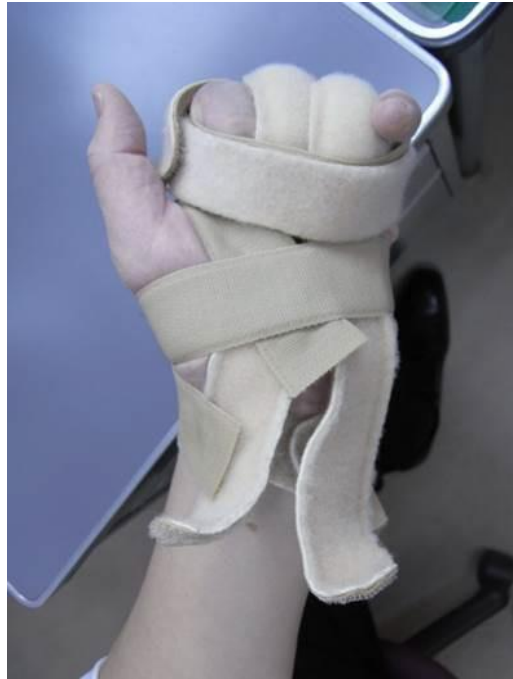**Figure 2.** (a) Antero-posterior view of the left hand on initial visit



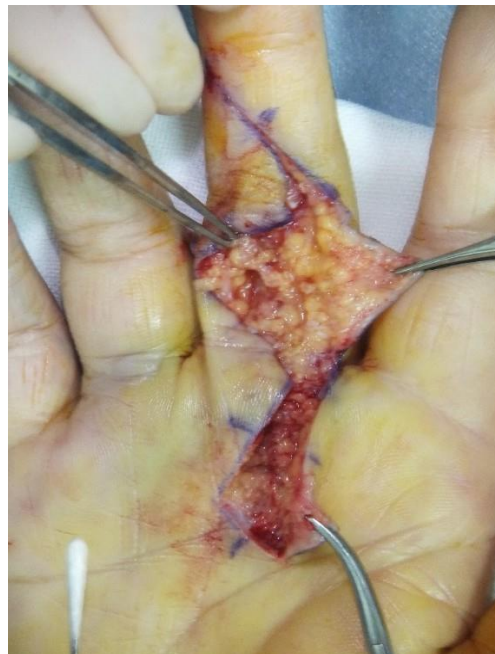**Figure 2.** (b) MRI on initial visit: A part of the middle finger metacarpal head had a bone fusion image



**Figure 3.** Intraoperative finding of case 1: There was a fistula in the metacarpal neck



**Figure 4.** Hand based splint: It started than weak power of traction and gradually lengthened wearing time in case 1 and 2



**Figure 5.** Intraoperative finding of case 2: There was inflammation along a tendon sheath and washed site of inflammation

### 3. DISCUSSION

The hand is easy to be injured a cut or a stab, and supportive inflammation may be caused when we do not provide appropriate treatment. [1] recommended hand infections are often clinically unsuspected, leading to delays in clinical diagnosis. [2] described anatomical grounds about a progression of hand infection style in 1939. The wound was small in case 1, but the infection was deep, and osteomyelitis was caused. Because the infection did not involve MP joint, the bone graft was not carried out and gave irrigation and

debridement, antibiotic agent feeding. MRI is useful for a diagnosis of metacarpal osteomyelitis, [3] recommended that they were aware of the possibility of cartilage and bone penetration, but found no signs until MRI revealed the overlying septic arthritis an osteomyelitis. About treatment of metacarpal osteomyelitis, we do it when we perform incision, irrigation, antibiotic agent feeding. Early diagnosis, early treatment is necessary in the pyogenic flexor tenosynovitis and metacarpal osteomyelitis [4- 7]. In our case, we resected thorough lavage and the pathologic tissue, and the infection healed. It is important to perform appropriate rehabilitation after finger infection calmed down to obtain good finger excursion, but there are few reports described about it [8]. Neviasser [9] recommended closed sheath irrigation for the treatment of pyogenic flexor tenosynovitis and emphasized the importance of starting active exercises soon after the operation. In our case, all cases started the active exercise of the finger from the next day of the surgery and conducted the training using the strap after surgery from one week. The patients conducted the exercise of distal interphalangeal joint and proximal interphalangeal joint in MP joint extended position by the rehabilitation. We used the strap one week when inflammation and edema were improved after surgery, and combined it with rehabilitation for acquisition of complicated exercise balance and obtained good excursion.

#### **4. CONCLUSION**

We obtained good results for two patients of the hand infection received surgery and a postoperative strap, rehabilitation, and we obtained good results, and thought that enforcement of appropriate exercise therapy and the rehabilitation for the ADL independence depending on a healing process was important after initial treatment.

#### **5. Acknowledgement**

Approval for this investigation was obtained from the institutional review board of Koishikawa Tokyo Hospital. Informed consent was provided by all patients who were included in the study; these participants will be informed about the publication of this article upon acceptance.

#### **6. Conflicts of Interest**

The authors have disclosed no potential conflicts of interest.

#### **7. REFERENCES**

- [1] Banerjee, Samik, et al. "Blastomycotic osteomyelitis: an unusual cause of hand swelling." *The Journal of Hand Surgery* Vol. 42, No. 11, 2017, p. 932-e1.
- [2] Kanavel, Allen Buckner. *Infections of the hand: a guide to the surgical treatment of acute and chronic supportive processes in the fingers, hand and forearm.* Lea & Febiger, 1921.
- [3] Kilian, Miroslav. "Clenched fist injury complicated by septic arthritis and osteomyelitis treated with negative pressure wound therapy: One case report." *Chinese Journal of Traumatology* Vol. 19, No. 3, 2016, pp. 176-78.
- [4] Hohendorff, Bernd, et al. "Treatment of digital pyogenic flexor tenosynovitis: single open debridement, irrigation, and primary wound closure followed by antibiotic therapy." *Archives of Orthopedic and Trauma Surgery* Vol. 137, No. 1, 2017, pp. 141-45.
- [5] Draeger, Reid W., and Donald K. Bynum Jr. "Flexor tendon sheath infections of the hand." *Journal of the American Academy of Orthopedic Surgeons* Vol. 20, No. 6, 2012, pp. 373-82.

[6] Draeger, Reid W., et al. "Corticosteroids as an adjunct to antibiotics and surgical drainage for the treatment of pyogenic flexor tenosynovitis." *JBJS* Vol. 92, No. 16, 2010, pp. 2653-62.

[7] Kakinoki, Ryosuke, Ryosuke Ikeguchi, and Takashi Nakamura. "Second dorsal metacarpal artery muscle flap: an adjunct in the treatment of chronic phalangeal osteomyelitis." *The Journal of Hand Surgery* Vol. 29, No. 1, 2004, pp. 49-53.

[8] Schnall, Stephen B., et al. "Tissue pressures in pyogenic flexor tenosynovitis of the finger compartment syndrome and its management." *Journal of Bone & Joint Surgery, British Volume* Vol. 78, No. 5, 1996, pp. 793-95.

[9] Neviasser, Robert J. "Closed tendon sheath irrigation for pyogenic flexor tenosynovitis." *The Journal of Hand Surgery* Vol. 3, No. 5, 1978, pp. 462-66.